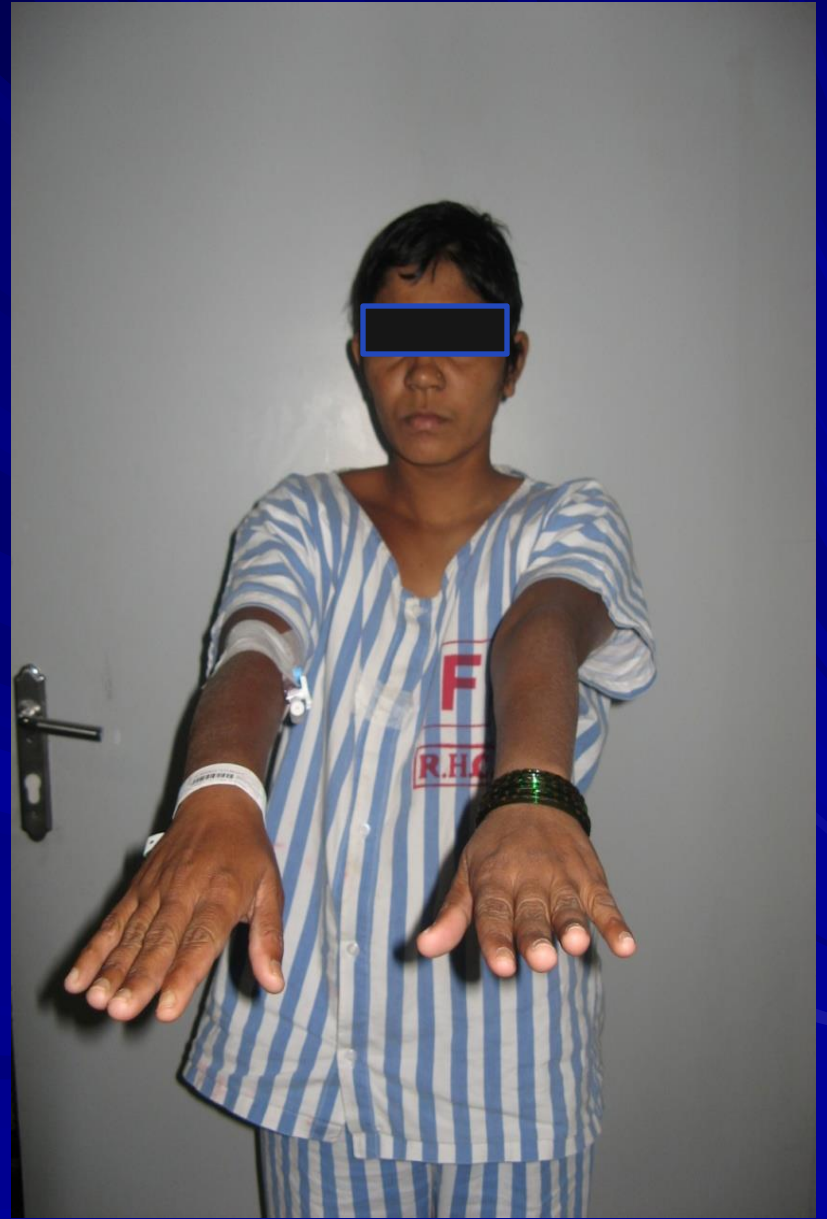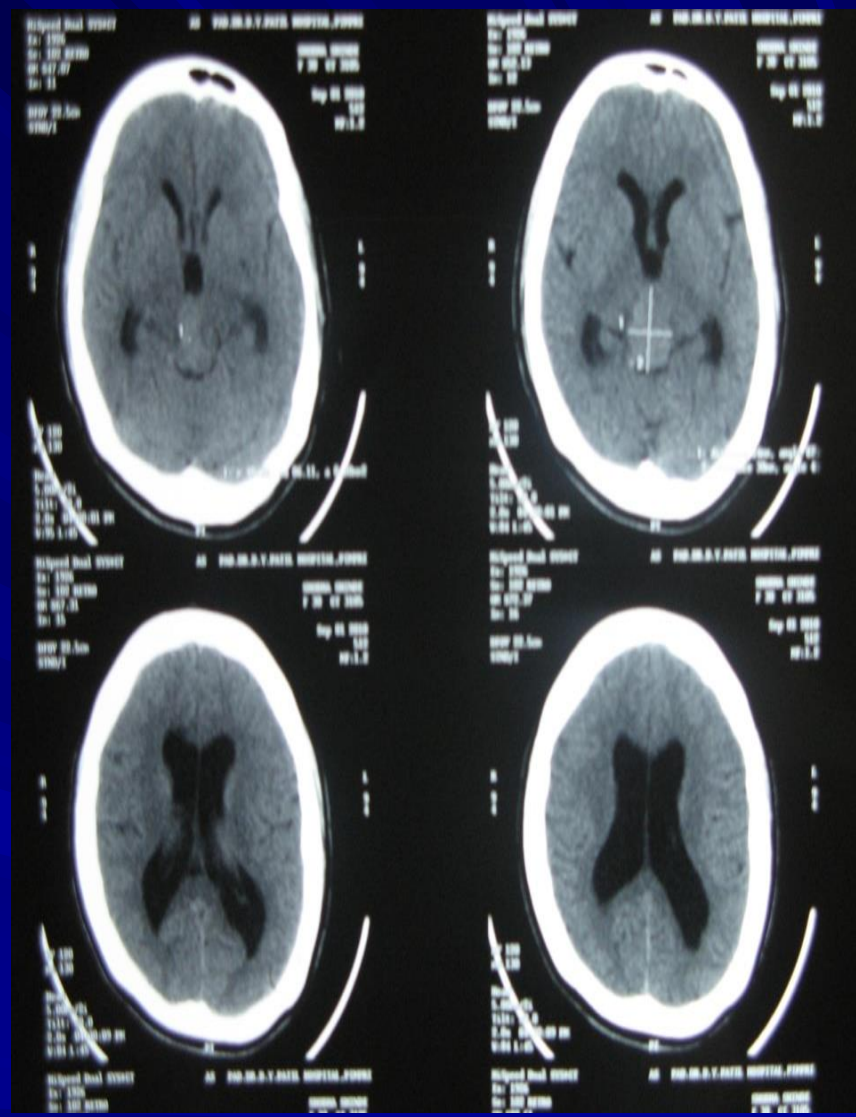
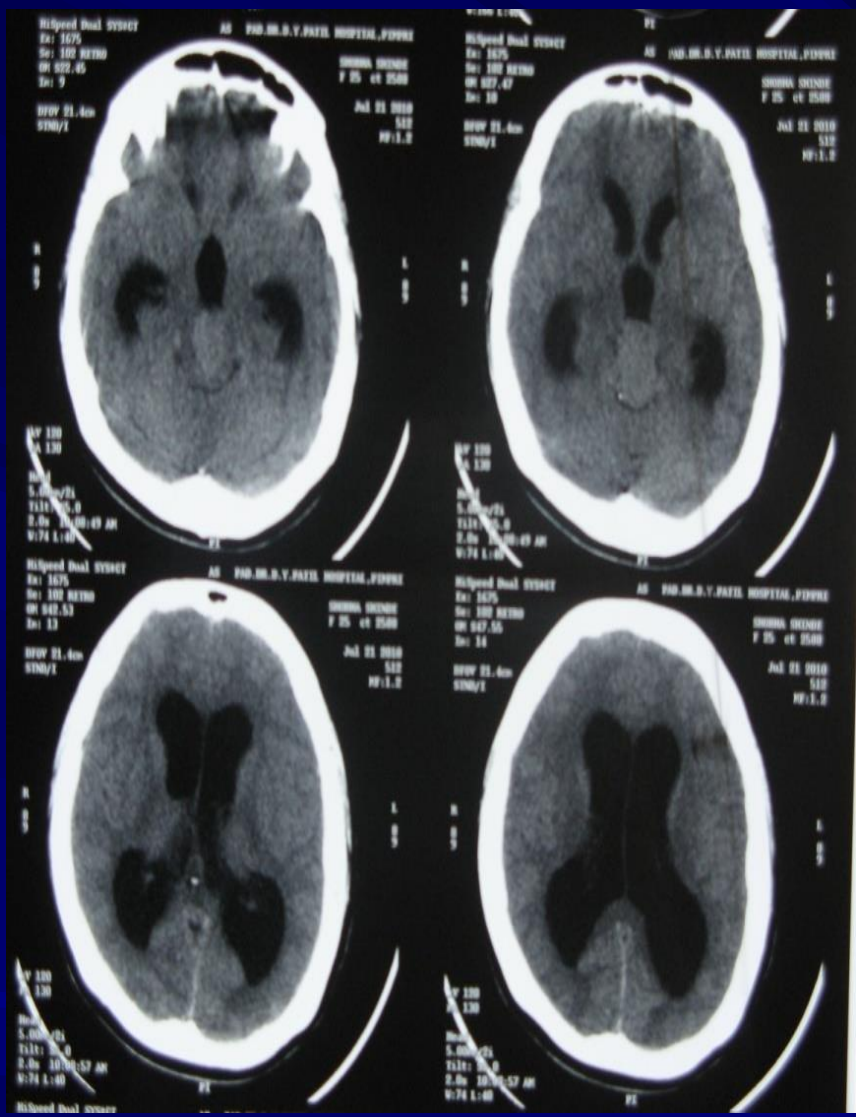


***III<sup>RD</sup> VENTRICULAR  
COLLOID CYST***

III<sup>rd</sup> Ventricular colloid Cyst more than  
25 cases operated



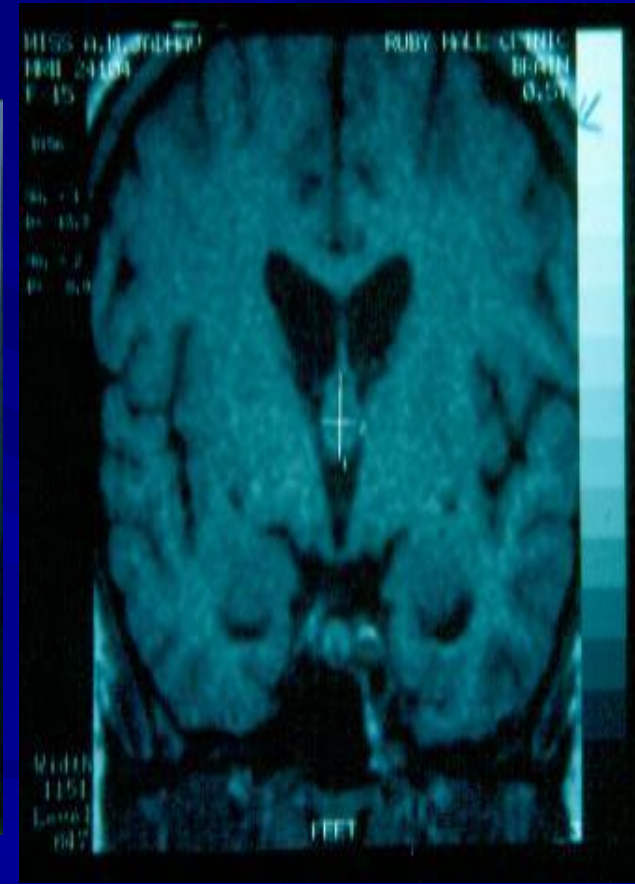
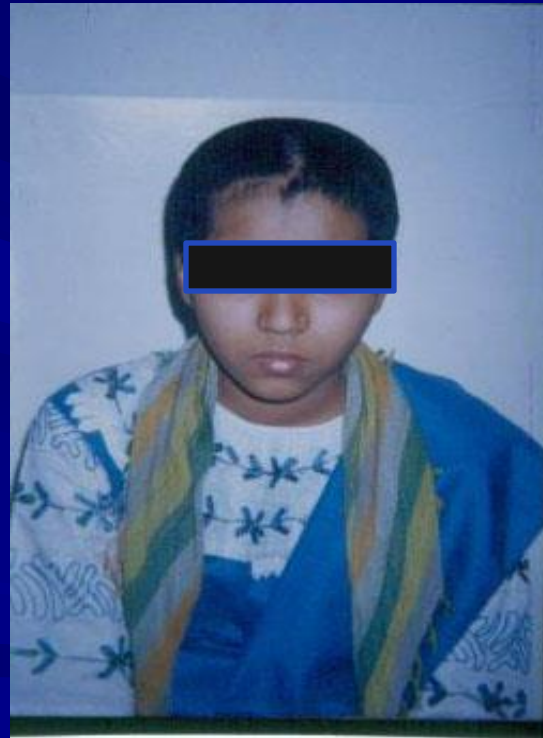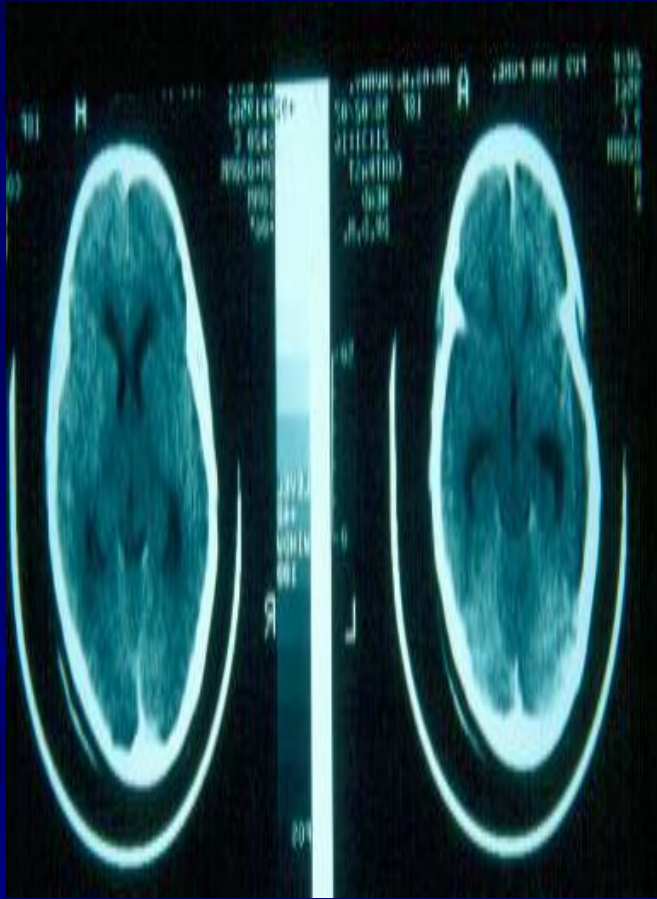


Pre Op

Post Op

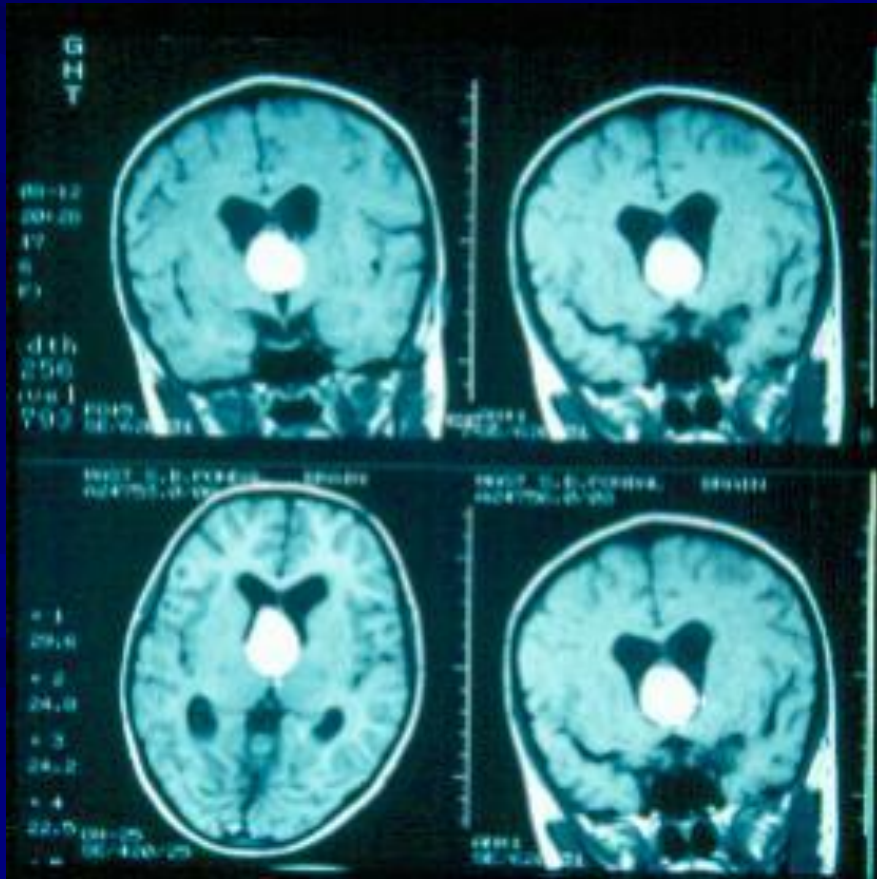
# Miss. Asha Jadhav

## IIIrd Vent. Colloid Cyst



# Mast. Baba Popal IIIrd Vent. Colloid Cyst

PRE-OP



POST-OP

