

DR.SANJAY. S. VHORA

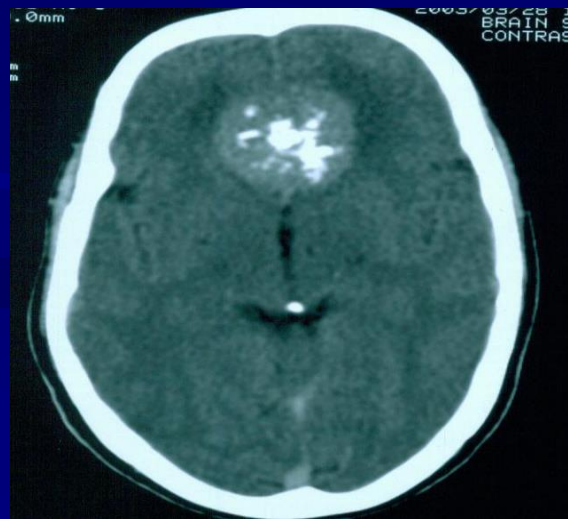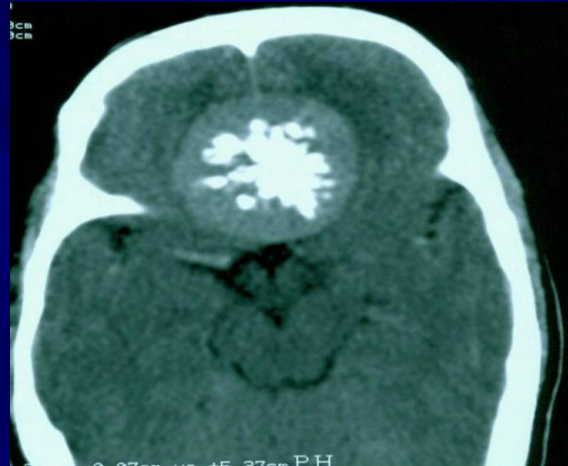CONSULTANT NEUROSURGEON

MENINGIOMA

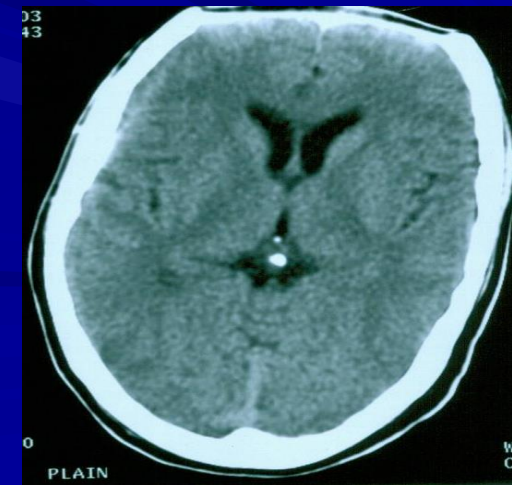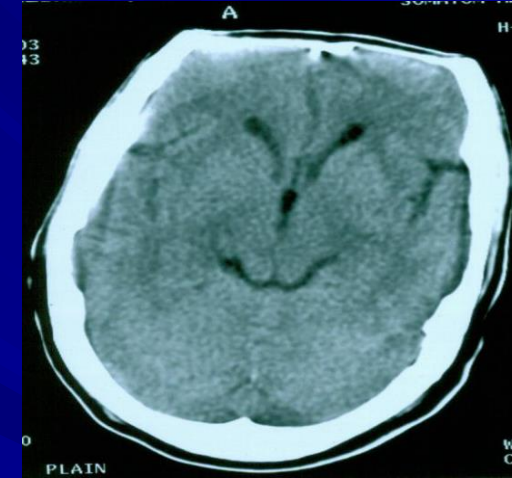
Meningioma cases more than 200 cases
operated

Baso Frontal Meningioma

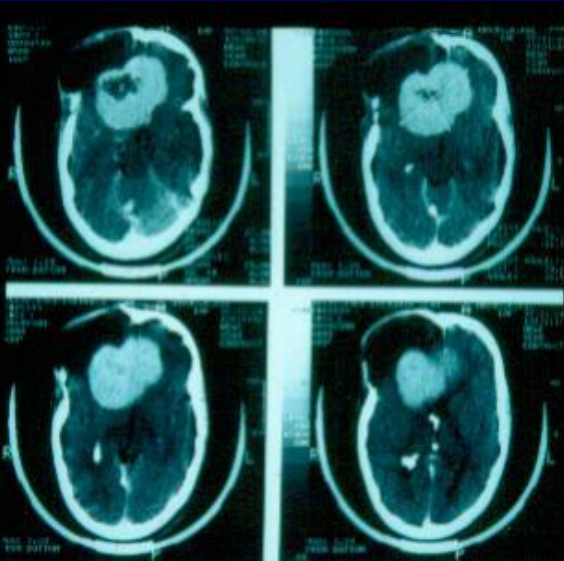
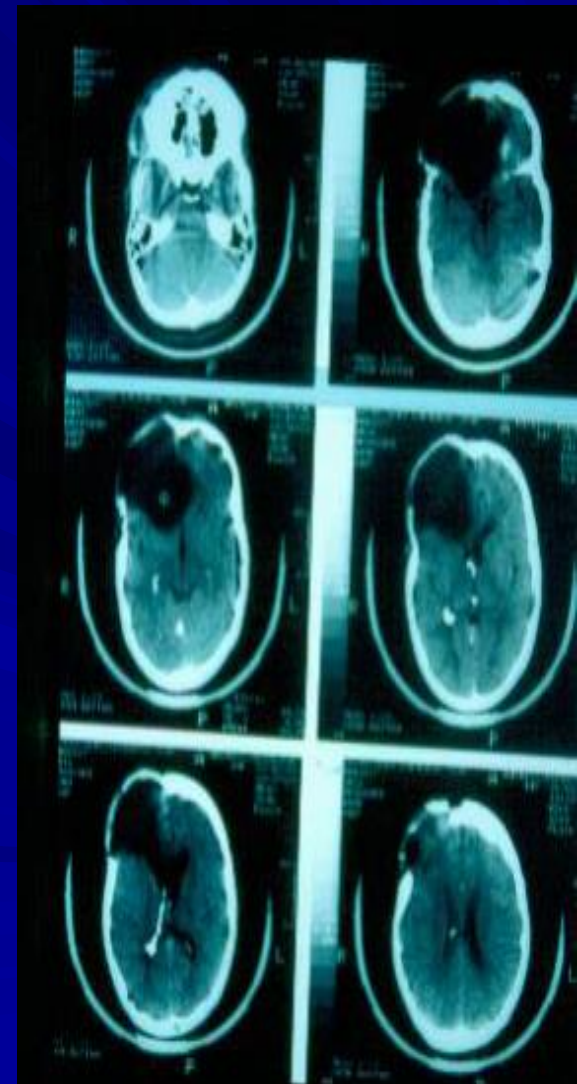
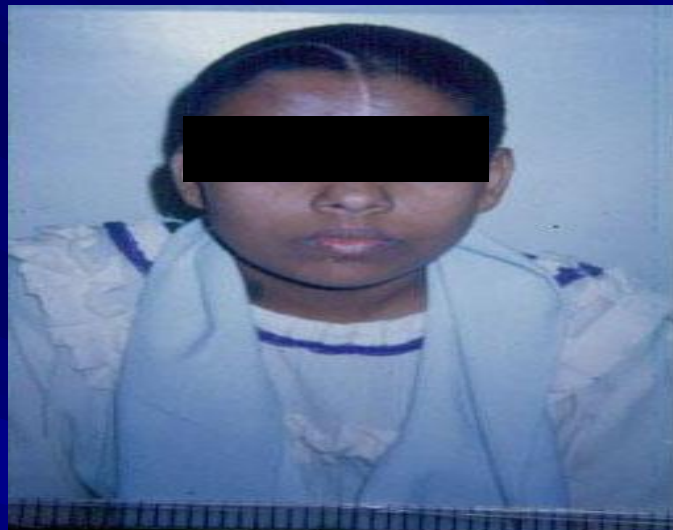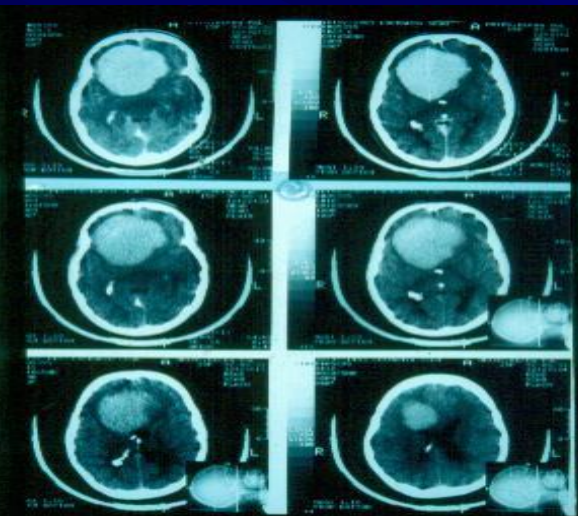
PRE-OP



POST-OP

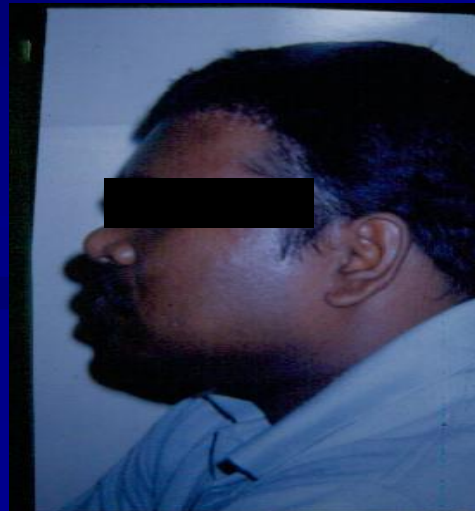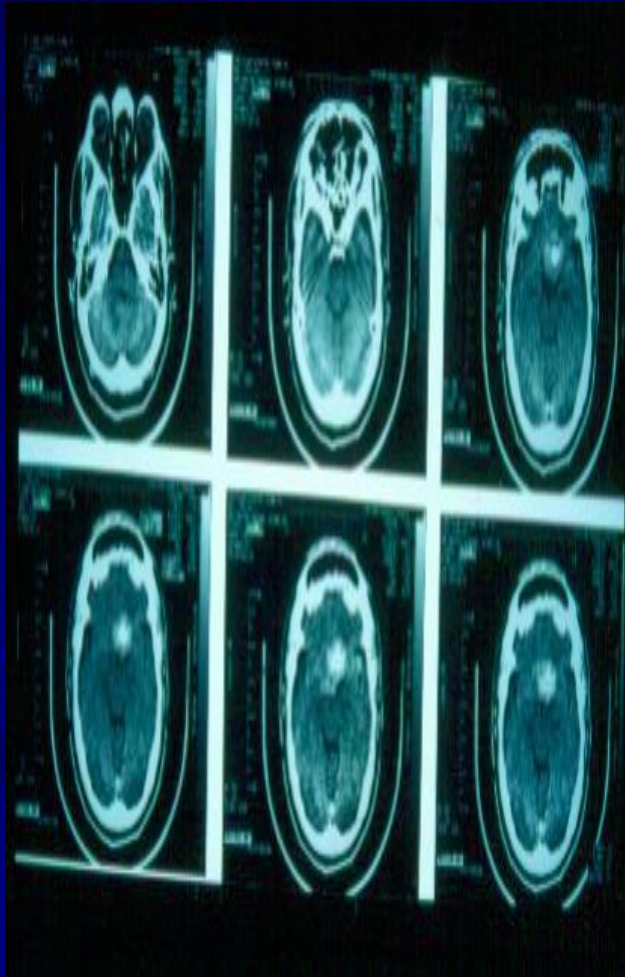


Meningioma

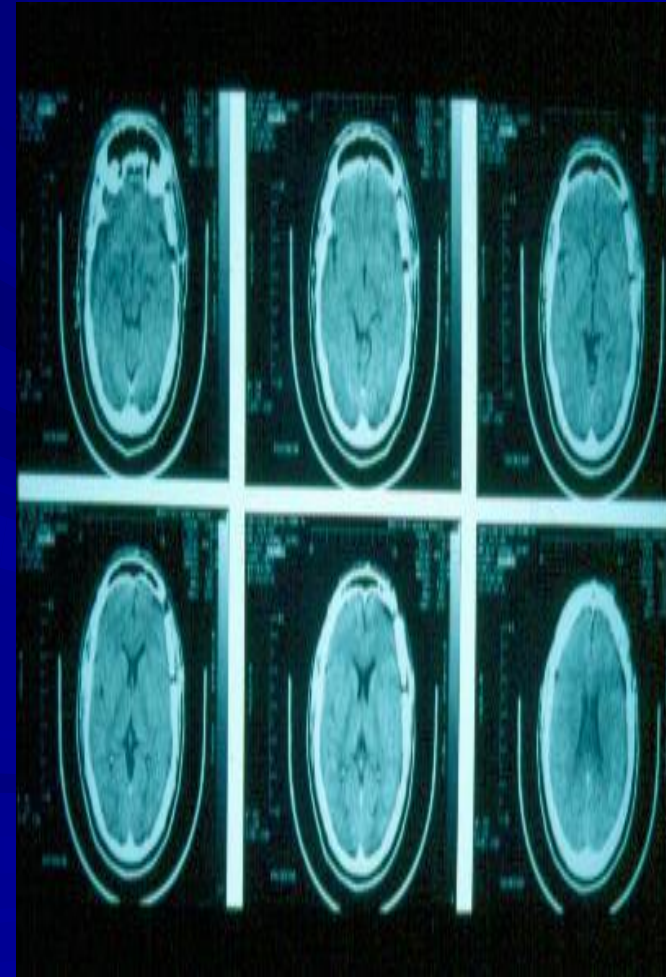


Supra-sellar Meningioma

PRE-OP

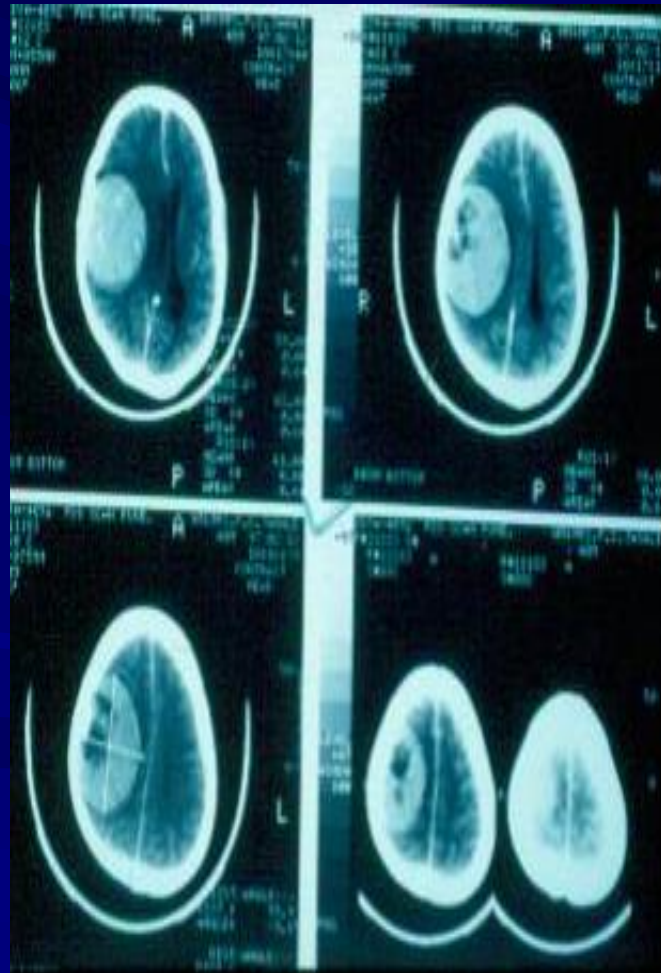


POST-OP



Rt-par-Meningioma

PRE-OP



POST-OP

